

Impact of Surgical Timing on Neurological Outcomes for Spinal Arachnoid Cyst: A Single Institution Series

Keshari Shrestha BS; Grégoire P. Chatain, MD; Stephanie Serva, MS; Michael W. Kortz, MBA; Ryan Ward BS; Michael Finn, MD

INTRODUCTION

- While surgery is the accepted treatment modality for symptomatic patients with spinal arachnoid cysts, there is a lack of literature pertaining to the management of minimally/asymptomatic patients.

OBJECTIVES

- To compare long-term neurological outcomes in patients with spinal arachnoid cysts who were managed conservatively versus surgically and to understand the natural progression of asymptomatic spinal arachnoid cysts.

METHODS

- Retrospective analysis of adult patients treated for spinal arachnoid cysts at our institution from 2010-2021.
- Study outcomes included functional neurologic outcomes, cyst recurrence, use of intra-operative ultrasound, and post-operative complications.

RESULTS

- 36 patients with spinal arachnoid cysts.
- Average age at diagnosis was 49.4 years (range 24-81) and 55.6% of patients were female.
- 18 managed surgically, 18 managed observationally.
- Common presenting symptoms included extremity weakness/numbness and bladder dysfunction.
- Post-operative complications ranged from spinal cord tethering, infection, CSF leak, worsening neurologic deficit, and arachnoiditis.
- 7 patients (38.9%) of patients who were initially managed observationally ultimately underwent surgical treatment due to neurological decline.
- Patients who were managed completely conservatively had lower McCormick scores both initially and at one year compared to patients who were managed surgically ($p=0.01$ and $p=0.008$ respectively).
- Additionally, at one year, there was no difference in McCormick scores between patients who were managed surgically and those who were initially managed conservatively and then subsequently underwent surgery secondary to neurologic decline ($p>0.99$).
- Intraoperative ultrasound was used in 57% of cases.
- Preoperative CT myelogram was obtained in 52% of patients.
- Post-operative cyst recurrence rates were similar in patients who underwent pre-operative MRI alone vs MRI+CT myelogram ($p=>0.99$).
- Post-operative cyst recurrence rates were similar in patients who underwent intraoperative ultrasound versus those who did not ($p=0.73$).

CONCLUSIONS

- A significant portion of patients who were initially managed conservatively eventually underwent surgery secondary to neurological decline.
- Patients who were managed completely conservatively had lower McCormick scores both initially and at one year compared to patients who were managed surgically.
- At one year, there was no difference in McCormick scores between patients who were managed surgically and those who were initially managed conservatively and then subsequently underwent surgery. This indicates delayed surgical intervention in minimally symptomatic patients does not seem to result in worse long-term neurofunctional outcomes.
- CT myelogram does not seem to add any useful value as a pre-operative adjunct diagnostic tool when compared to MRI alone.
- Management of spinal arachnoid cysts is controversial. While surgical management is the accepted treatment modality in patients with symptomatic disease, more research is necessary to elucidate the role of conservative management in asymptomatic and minimally symptomatic patients.

While a significant proportion of patients with spinal arachnoid cysts who were managed conservatively ultimately underwent surgery secondary to neurologic decline, they still had similar post-operative McCormick functional outcome scores compared to patients who were initially managed surgically at the time of diagnosis.

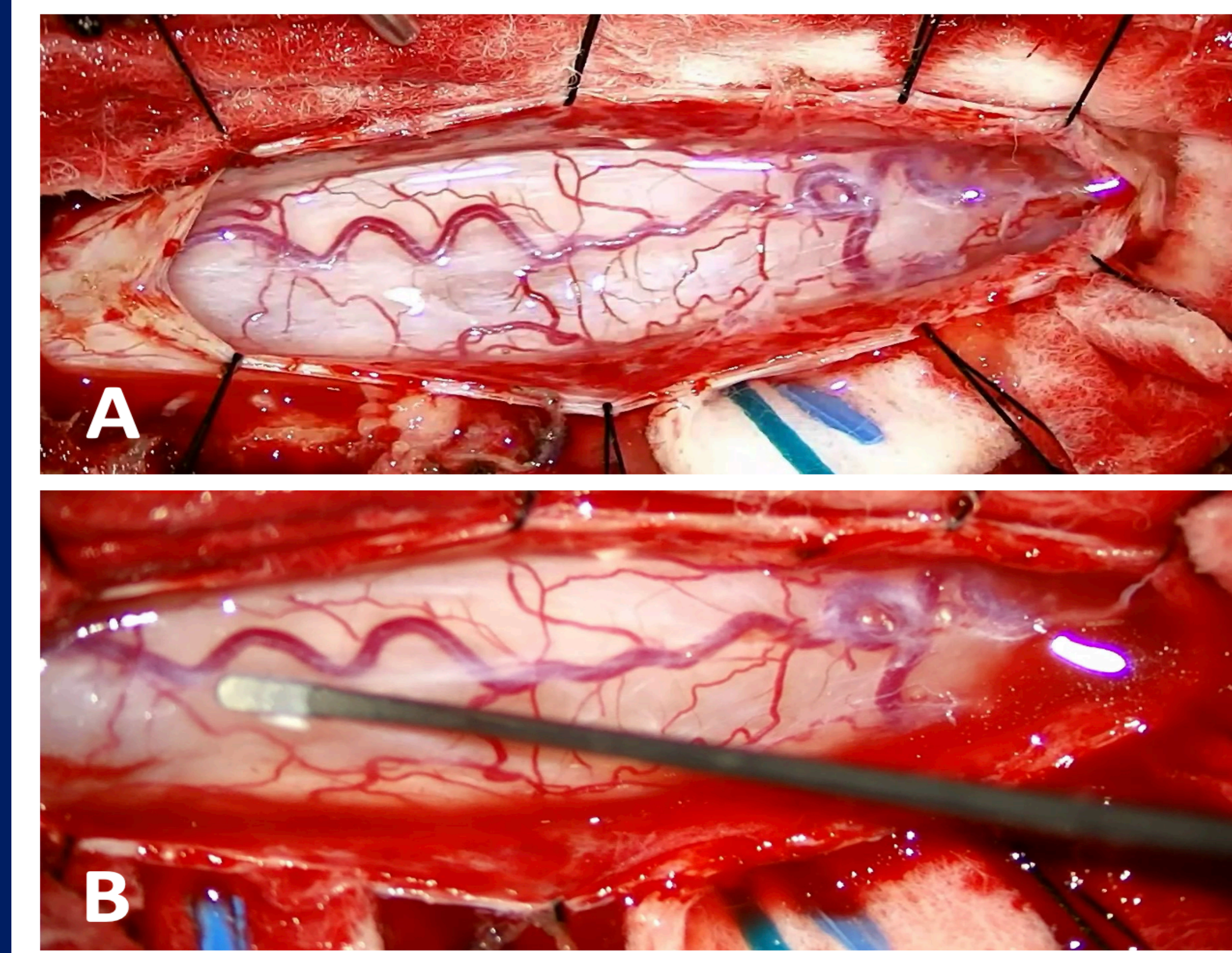


Figure 1: Intraoperative pictures showing surgical exploration of intradural arachnoid cyst

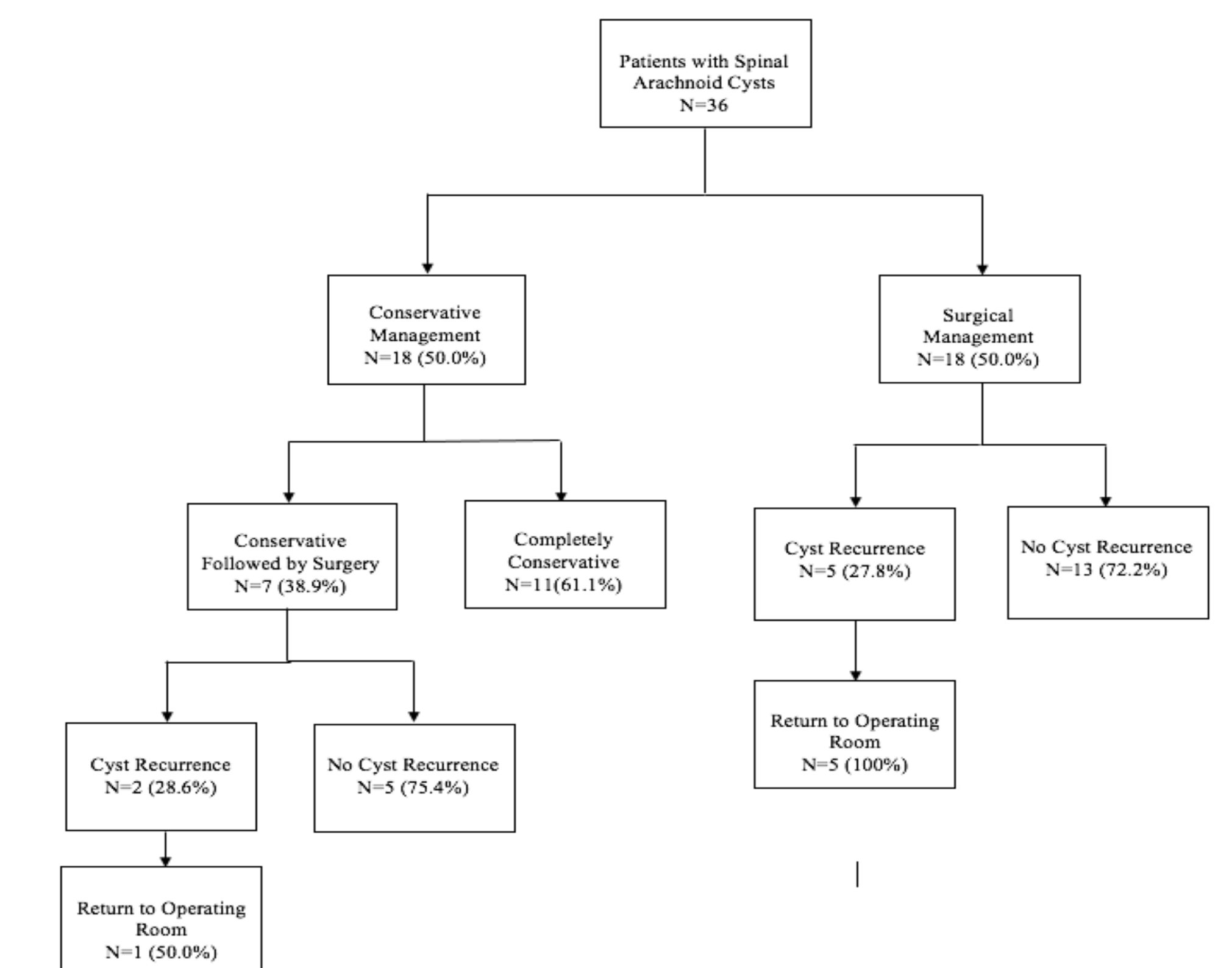


Figure 1: Flow diagram illustrating the different treatment avenues for patients with spinal arachnoid cysts

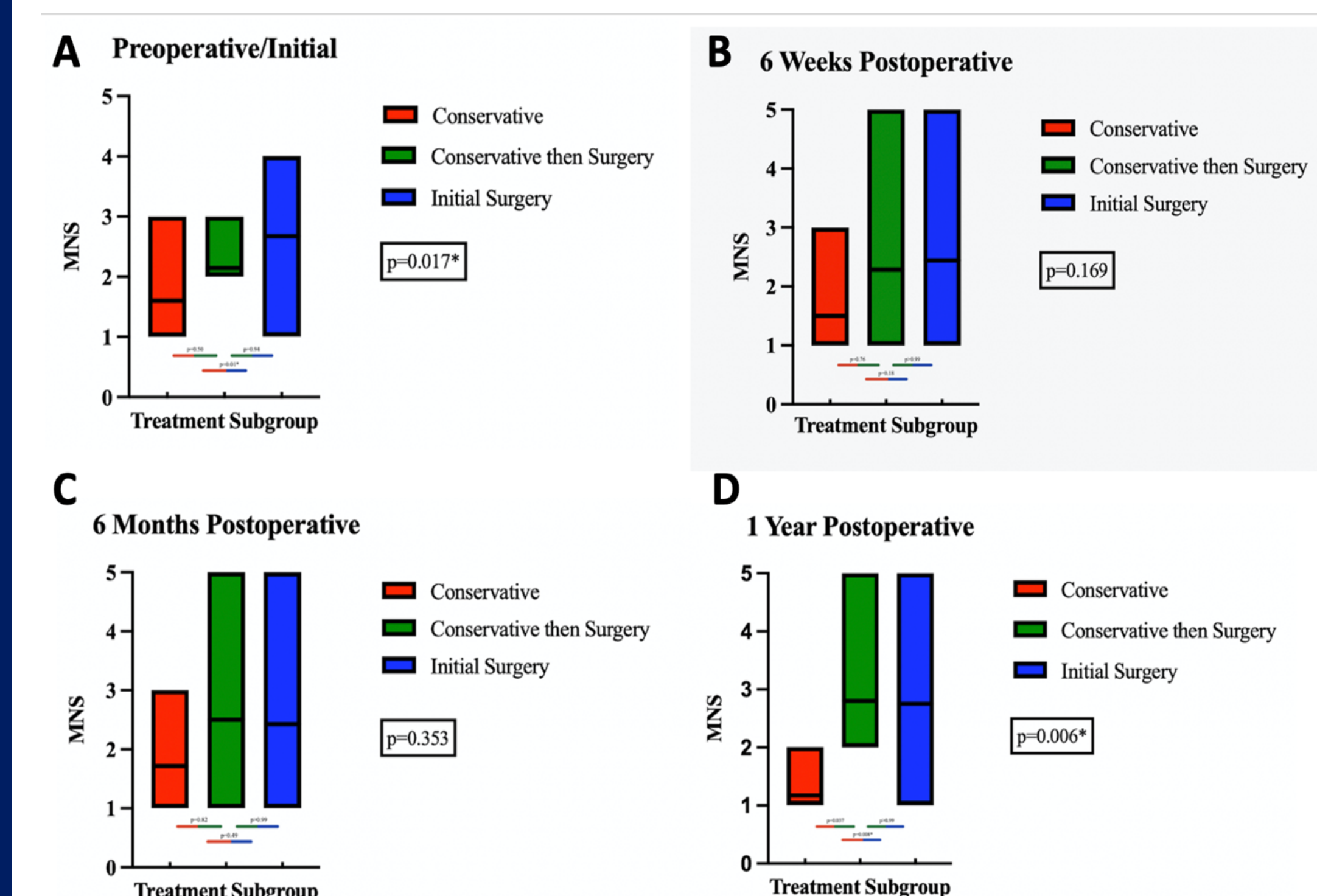


Figure 2: Box plot showing average preoperative/initial and postoperative MNS scores at 6 weeks, 6 months and 1 year.